Multimodality Imaging of the Thoracic Aorta

Steven Goldstein MD, FACC
Director Noninvasive Cardiology
MedStar Heart and Vascular Institute
Washington Hospital Center
Saturday, October 8, 2016

DISCLOSURE

I have **N O** relevant financial relationships

Sunset in Kentucky

GUIDELINES AND STANDARDS

Multimodality Imaging of Diseases of the Thoracic Aorta in Adults: From the American Society of Echocardiography and the European Association of Cardiovascular Imaging

Endorsed by the Society of Cardiovascular Computed Tomography and Society for Cardiovascular Magnetic Resonance

Steven A. Goldstein, MD, Co-Chair, Arturo Evangelista, MD, FESC, Co-Chair, Suhny Abbara, MD, Andrew Arai, MD, Federico M. Asch, MD, FASE, Luigi P. Badano, MD, PhD, FESC, Michael A. Bolen, MD, Heidi M. Connolly, MD, Hug Cuéllar-Calàbria, MD, Martin Czerny, MD, Richard B. Devereux, MD, Raimund A. Erbel, MD, FASE, FESC, Rossella Fattori, MD, Eric M. Isselbacher, MD, Joseph M. Lindsay, MD, Marti McCulloch, MBA, RDCS, FASE, Hector I. Michelena, MD, FASE, Christoph A. Nienaber, MD, FESC, Jae K. Oh, MD, FASE, Mauro Pepi, MD, FESC, Allen J. Taylor, MD, Jonathan W. Weinsaft, MD, Jose Luis Zamorano, MD, FESC, FASE, Contributing Editors: Harry Dietz, MD, Kim Eagle, MD, John Elefteriades, MD, Guillaume Jondeau, MD, PhD, FESC, Hervé Rousseau, MD, PhD,

J Am Soc Echocardiogr 2015;28:119-82

www.asecho.org → Guidelines

Imaging Modalities

Imaging Techniques

- Chest X-ray
- Echo (TTE, TEE, 3D-echo, epiaortic)
- Intravascular echo (IVUS)
- Intracardiac echo (ICE)
- CT/MDCT
- Magnetic resonance imaging
- Aortography

Imaging Techniques

- Chest X-ray
- **Echo (TTE, TEE, 3D-echo,** epiaortic**)**
- Intravascular echo (IVUS)
- Intracardiac echo (ICE)
- **CT/MDCT**
- **Magnetic resonance imaging**
- Aortography

Acute Aortic Syndromes

Heart 2001;**85**:365-68

Editorial

Acute aortic syndrome

Although the chest pain of acute aortic dissection is widely recognised, less consideration has been given to pain associated with other aortic pathologies. In light of contemporary concepts in aortic pathology we would like to present the pathology of a new cardiovascular syndrome—acute aortic syndrome (AAS).[1]

Isidre Vilacosta and José Alberto San Roman

Acute Aortic Syndromes

- Heterogeneous group of conditions
- Disruption of the aortic wall
- Similar clinical picture
  - Chest and/or back pain (“aortic pain”)
  - Usually underlying hypertension
- Need for prompt diagnosis → urgent care

Acute Aortic Syndromes

- Classic aortic dissection
- Intramural hematoma (variant of AD)
- Penetrating atherosclerotic aortic ulcer
- Ruptured/leaking aortic aneurysm

Aortic trauma usually considered separately

Acute Aortic Syndromes

- Delay in recognition and treatment is associated with unacceptable increase in mortality
- Signs and symptoms may be subtle/atypical
- Diagnosis requires high index of suspicion

Acute Aortic Syndromes Imaging Modalities

Rapid, accurate diagnosis essential

- CT-scan
- Echocardiography (TTE;**TEE**)
- Magnetic resonance imaging

Preferred in acute setting

Aortic Dissection

Aortic Dissection



Adventitia
Media
Intima

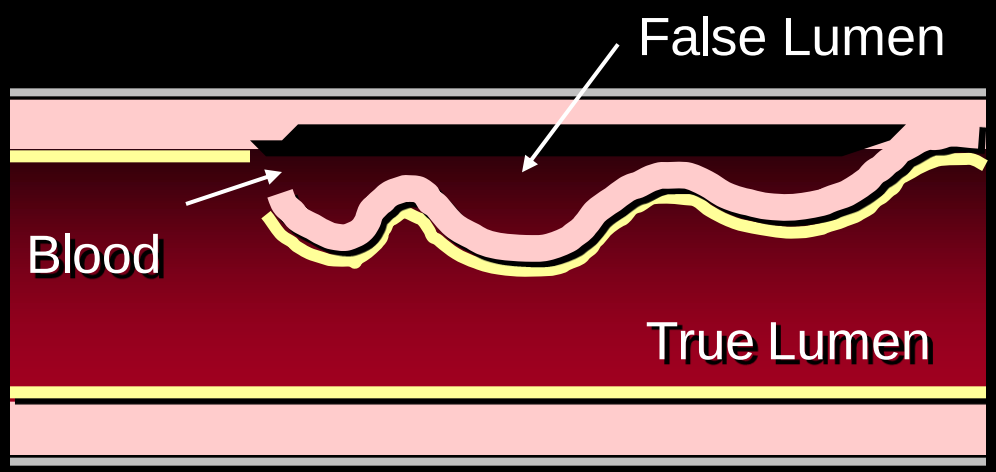

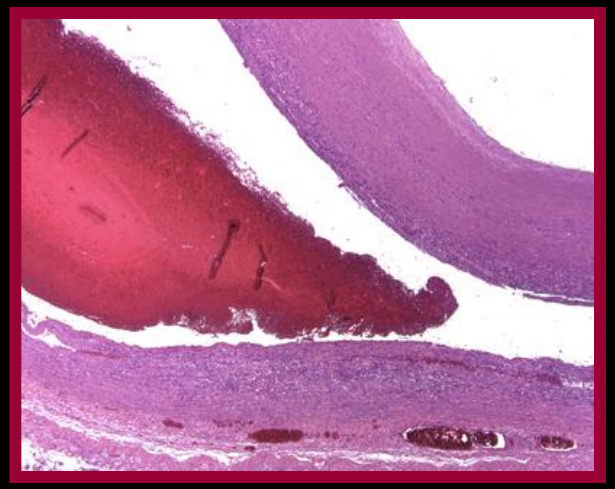

Aortic Dissection - Imaging Primary Objectives

- Identify entry site
- Determine type A vs B
- Involvement of coronary arteries ?
- Identify complications:
  - Presence, severity, mechanism of AR
  - Pericardial or pleural effusion
  - Rupture ?
  - Branch ischemia

Table 9 Recommendation for choice of imaging modality for **aortic dissection**

Modality	Recommendation	Advantages	Disadvantages
CT	First-line	• Initial test in >70% of patients* • Widely available, quickest diagnostic times • Very high diagnostic accuracy • Relatively operator independent • Allows evaluation of entire aorta, including arch vessels, mesenteric vessels and renal arteries	• Ionizing radiation exposure • Requires iodinated contrast material • Pulsation artifact in ascending aorta (can be improved with ECG gating)
TEE	First- and second-line	• Very high diagnostic accuracy in thoracic aorta • Widely available, portable, convenient, fast • Excellent for pericardial effusion, and presence, degree and mechanism(s) of AR and LV function • Can detect involvement of coronary arteries • Safely performed on critically ill patients, even those on ventilators • Optimal procedure for guidance in OR	• Operator dependent (depends on skill of operator) • "Blind spot" upper ascending aorta, proximal arch • Not reliable for cerebral vessels, celiac trunk, SMA, etc. • Reverberation artifacts can potentially mimic dissection flap (can be differentiated from flaps in vast majority) • Semi-invasive
TTE	Second-line	• Often initial imaging modality in ER • Provides assessment of LV contractility, pericardial effusion, RV size and function, PA pressure • Presence and severity of AR	• Sensitivity not sufficient distal to aortic root • Descending thoracic aorta imaged less easily and accurately • Misses IMH and PAU
MRI	Third-line	• 3D multiplanar, and high resolution • Very high diagnostic accuracy • Does not require ionizing radiation or iodinated contrast • Appropriate for serial imaging over many years	• Less widely available • Difficult monitoring critically ill patients • Not feasible in emergent or unstable clinical situations • Longer examination time • Caution with use of gadolinium in renal failure
Angiography	Fourth-line	• Rarely necessary	• Often misses IMH (up to 10%–20% of ADs) • Long diagnostic time • Requires ICM • Morbidity • Less sensitivity than CT, TEE, and MRI

AD, Aortic dissection; *ECG*, electrocardiographic; *ER*, emergency room; *ICM*, iodinated contrast media; *IMH*, intramural hematoma; *LV*, left ventricular; *OR*, operating room; *PA*, pulmonary artery; *PAU*, penetrating atherosclerotic ulcer; *RV*, right ventricular; *SMA*, superior mesenteric artery.
*In IRAD.

Imaging Modalities for Aortic Dissection

CT-Scan

- Initial test in >70% of patients (IRAD)
- Widely available, quickest diagnostic times
- Very high diagnostic accuracy
- Relatively operator independent
- Allows evaluation of entire aorta
  (including arch vessels, mesenteric vessels, and renal arteries)

CT-Scan for Aortic Dissection
Disadvantages

- Ionizing radiation exposure
- Requires iodinated contrast material
- Pulsation artifact in ascending aorta
  (can be improved with ECG gating)

Imaging Modalities for Aortic Dissection

TEE

- Very high diagnostic accuracy
- Widely available, portable, convenient, fast
- Excellent for:
  - Pericardial effusion
  - Presence, degree, mechanism of AR
  - L V function
- Can detect involvement of coronary arteries
- Safely performed on critically ill patients
- Optimal procedure for guidance in OR

Detection of Aortic Dissection
Accuracy of TEE

Author	Year	n	With Diss'n	Sens	Spec
Erbel	1989	164	82	**99%**	**98%**
Hashimoto	1989	22	22	**100%**	**N/A**
Adachi	1991	45	45	**98%**	**N/A**
Ballal	1992	61	34	**97%**	**100%**
Simon	1992	32	28	**100%**	**100%**
Nienaber	1993	110	44	**98%**	**77%**
Kang	1998	200	100	**100%**	**91%**
Totals		655	376	**99%**	**94%**

TEE for Aortic Dissection
Disadvantages

- Depends on skill of operator
- “Blind spot” upper ascending aorta
- Not reliable for cerebral vessels, mesenteric vessels, renal arteries
- Semi-invasive
- Reverberation artifacts (rarely a problem)

Imaging Modalities for Aortic Dissection

MRI

- Very high diagnostic accuracy
- 3D multiplanar and high resolution
- Does not require ionizing radiation or iodinated contrast material
- Appropriate for serial imaging over many years

MRI for Aortic Dissection
Disadvantages

- Less widely available
- Difficult monitoring critically ill patients
- Longer examination time
- Not feasible in emergent of unstable clinical situations
- Caution with use of gadolinium in renal failure

Diagnosis of Aortic Dissection

Comparative Study of Spiral CT, MRI, TEE

49 suspected aortic dissection

25 had dissection (18 type A; 7 type B)

	Sensitivity	Specificity	Time
Spiral CT	**100%**	**100%**	28 min
MRI	**100%**	**94%**	27 min
TEE	**100%**	**94%**	45 min

Sommer Radiology 199:347(1996)

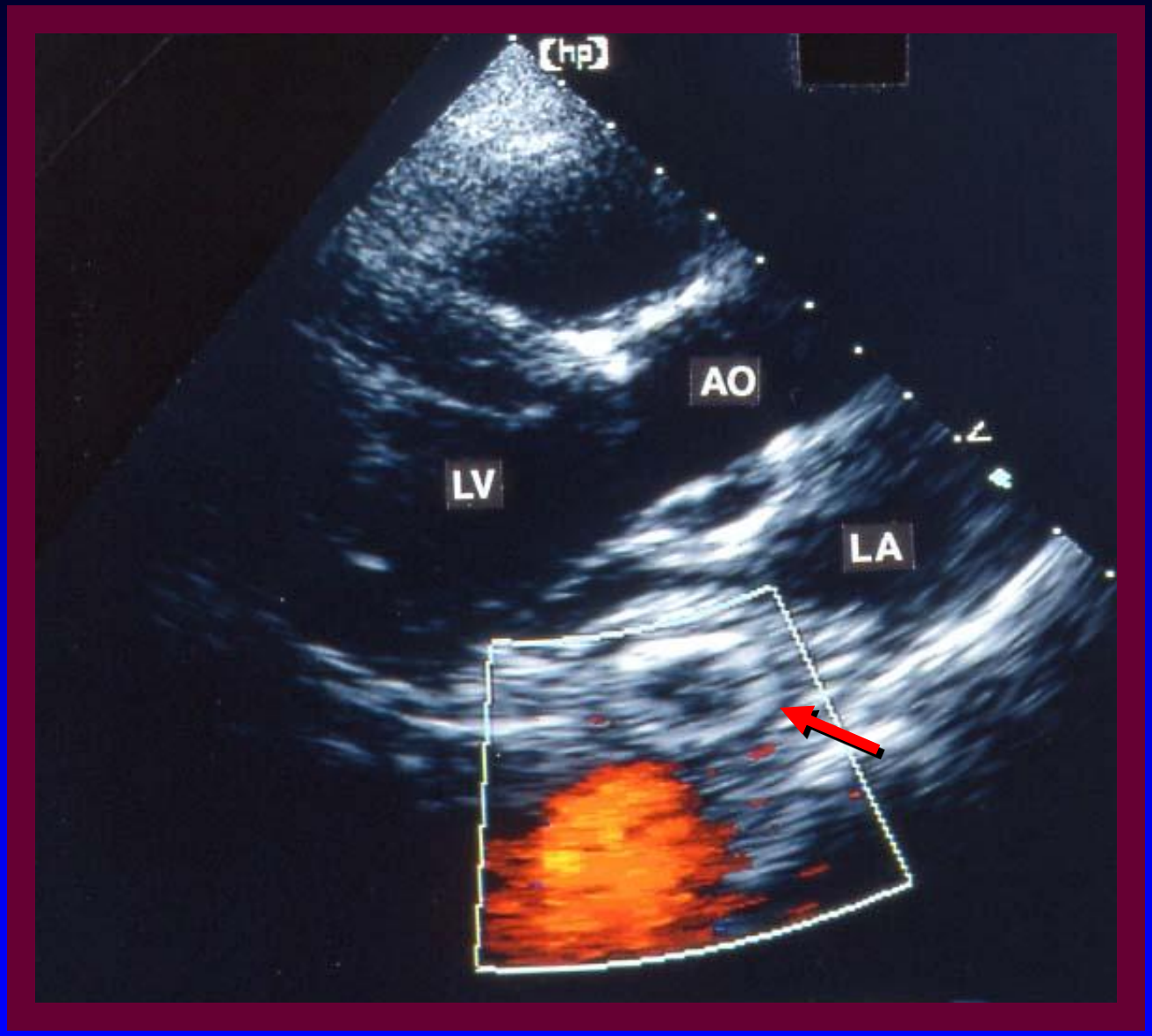
hp
AO
LV
LA

Aortic Dissection
2D-Echo Findings

- **Hallmark: dissection flap**
- Double-channel aorta (TL and FL)
- Dilated aorta (usual)
- Re-entry sites (ostia of intercostals)
- “Cobwebs” (false lumen)
- Aortic insufficiency
- Pericardial and/or pleural effusion

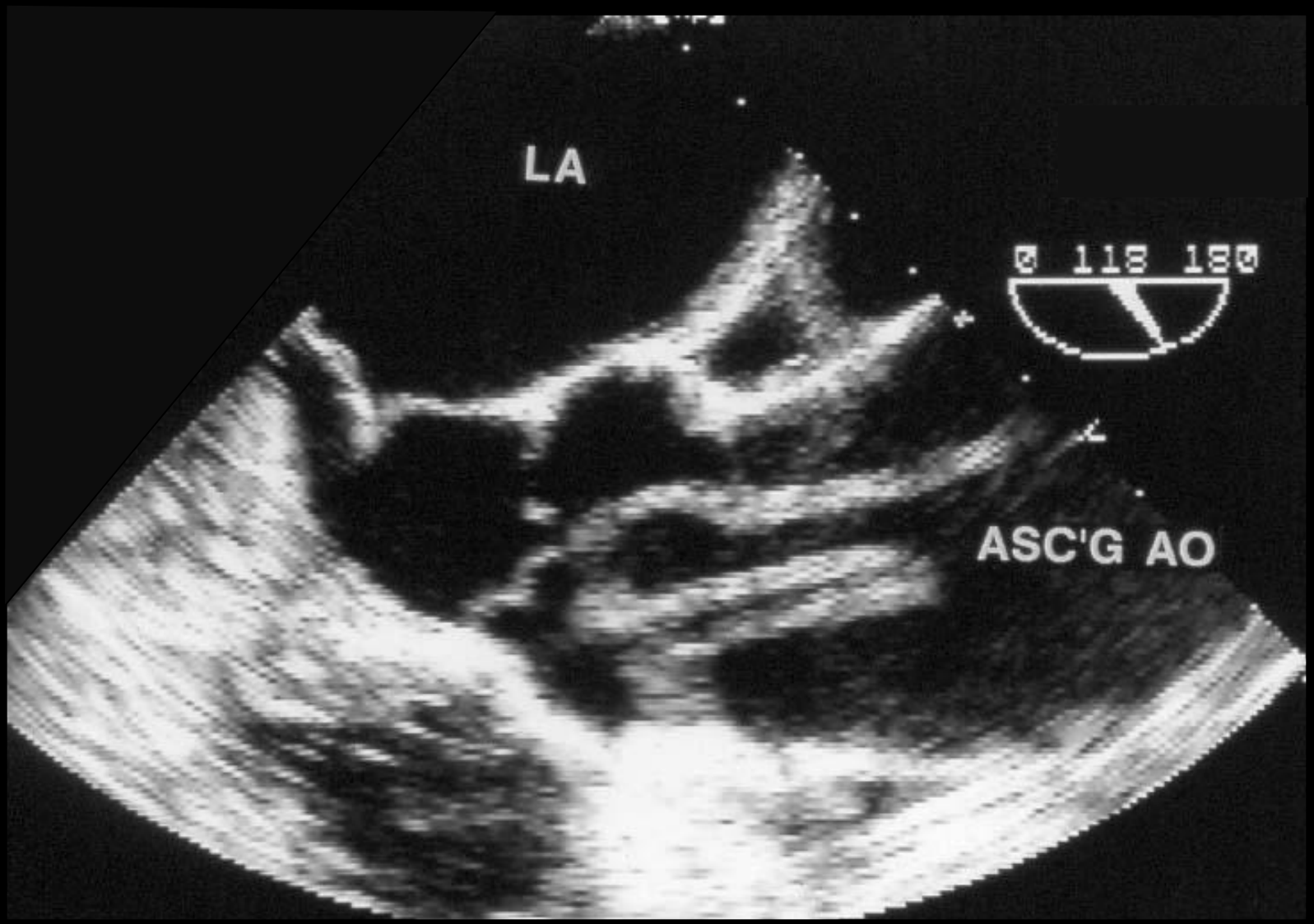
LA
0 118 180
ASC'G AO

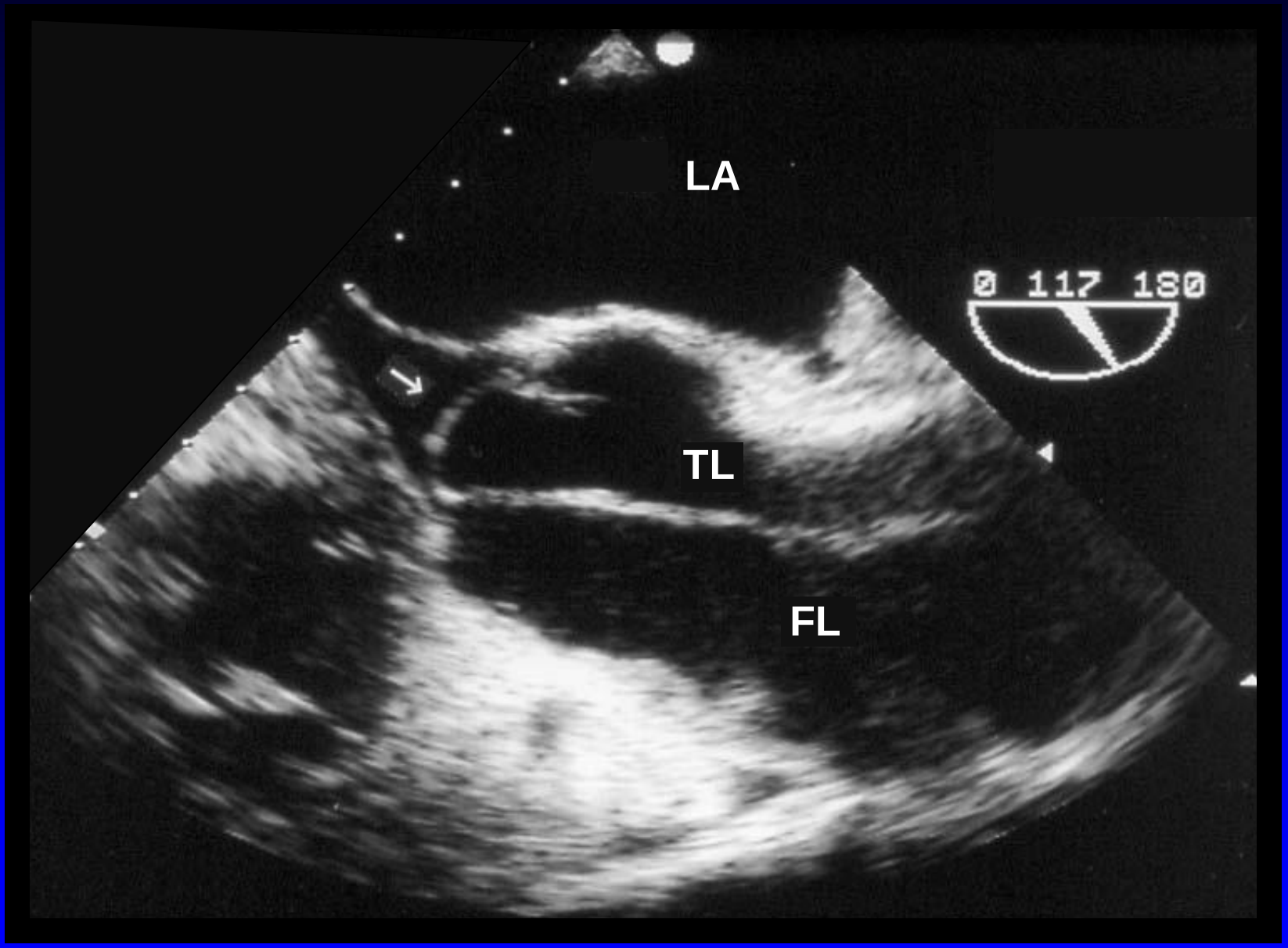
LA
0 117 180
TL
FL

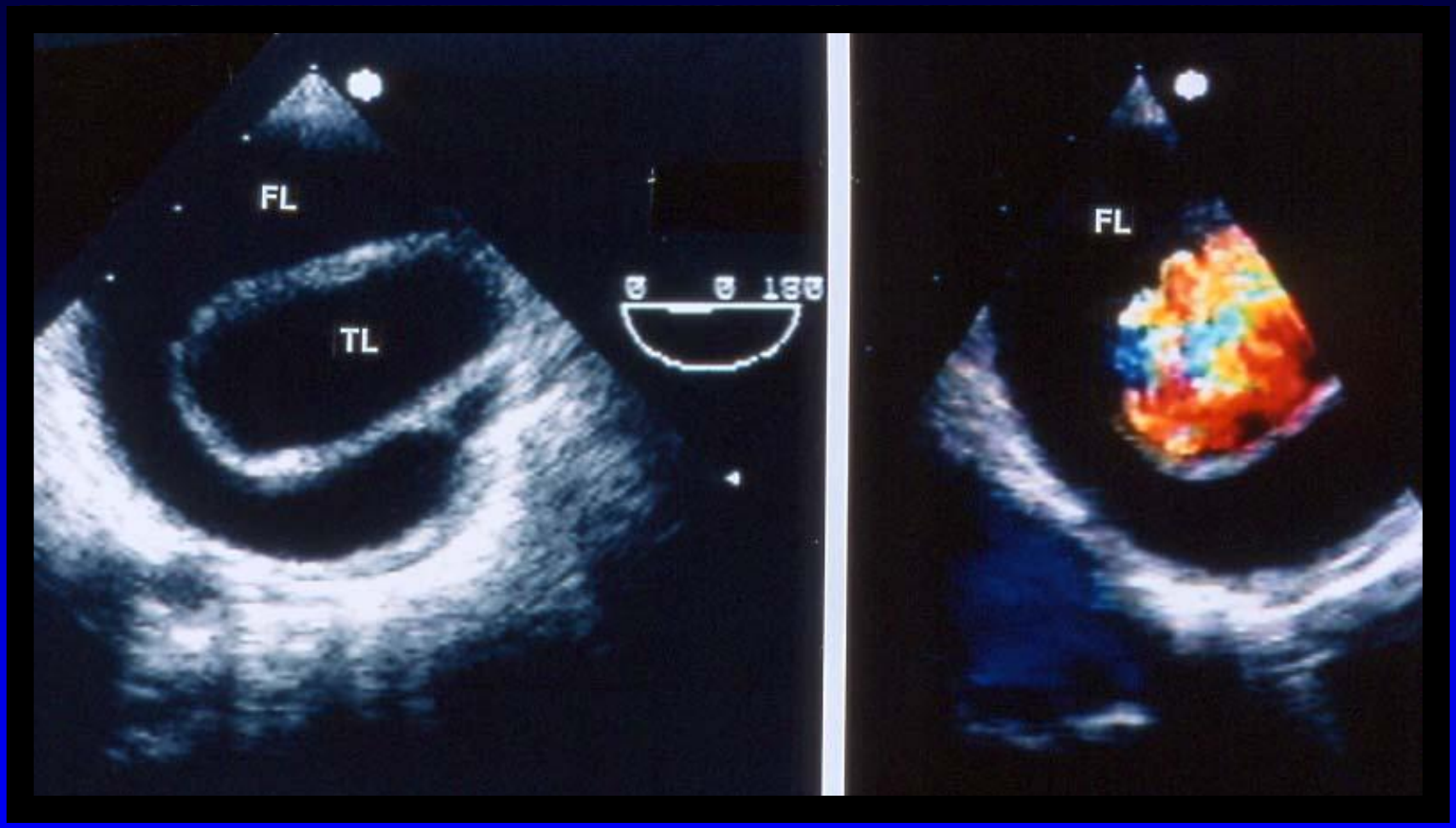
FL
TL
FL

Descending Thoracic Aorta

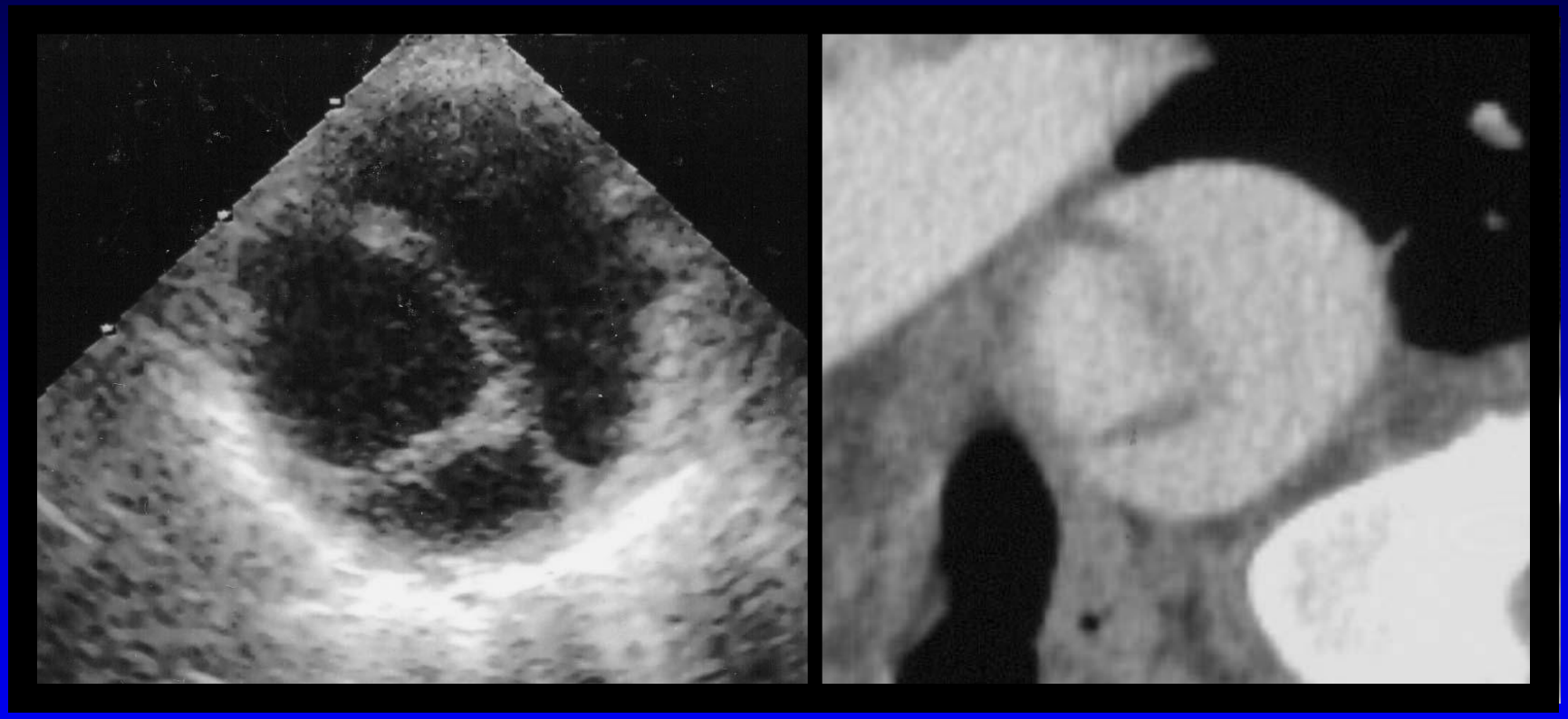

TEE CT-scan

Aortic Arch

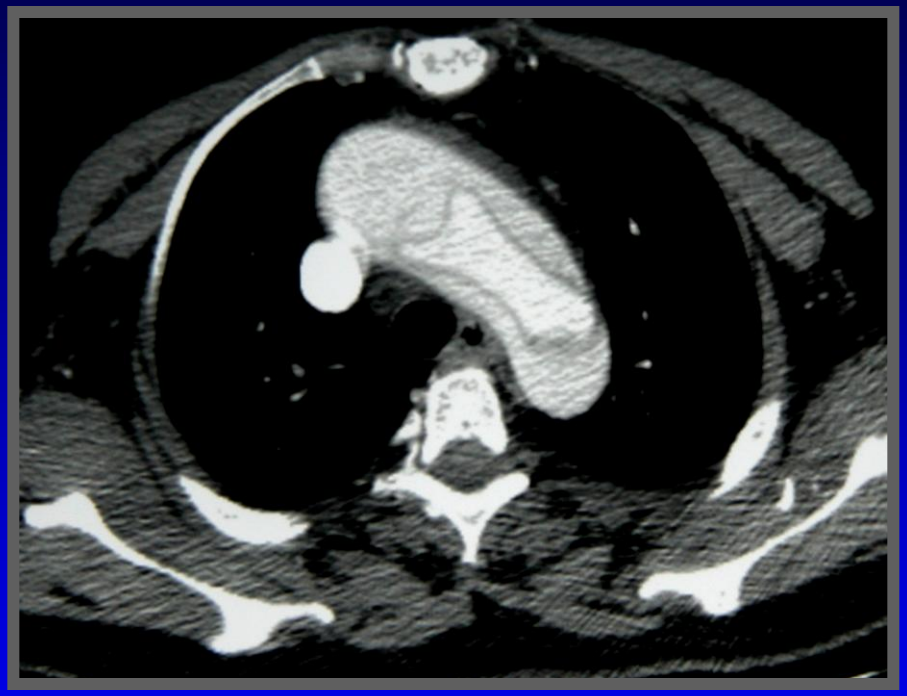

CT-scan

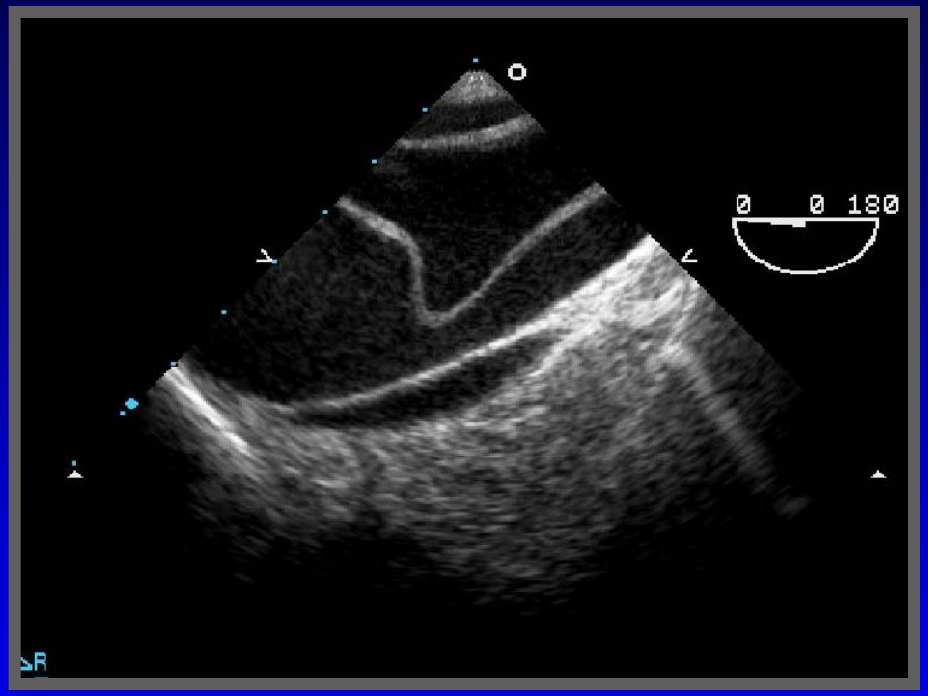

TEE

Aortic Regurgitation

Mechanisms of Aortic Regurgitation

- Dilatation of aortic root leading to incomplete aortic leaflet copatation
- Cusp prolapse
- Disruption of aortic annular support resulting in flail leaflet
- Invagination of dissection flap through the aortic valve in diastole
- Pre-existing aortic valve disease (eg,Bic AoV)

Mechanisms of Aortic Regurgitation

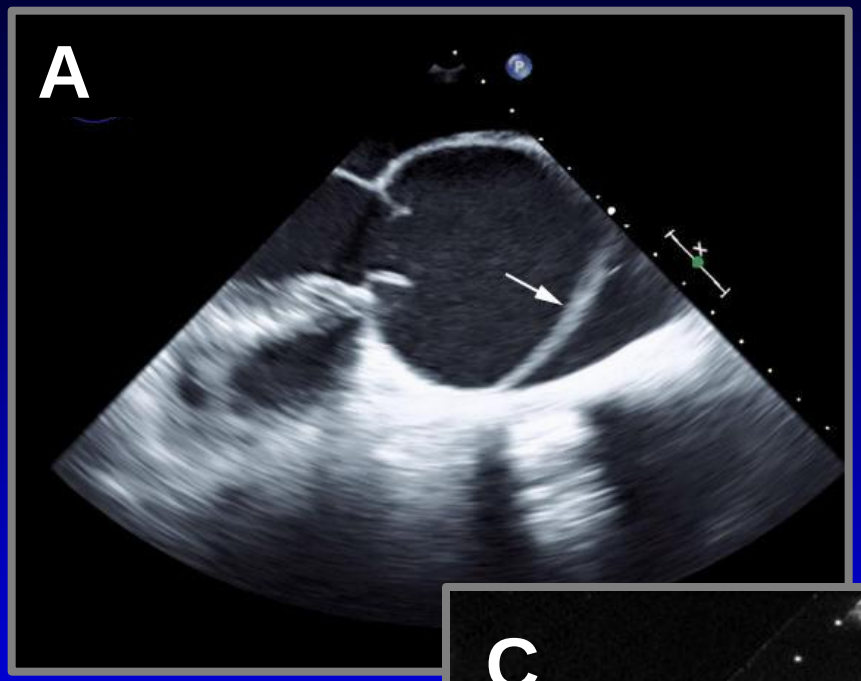

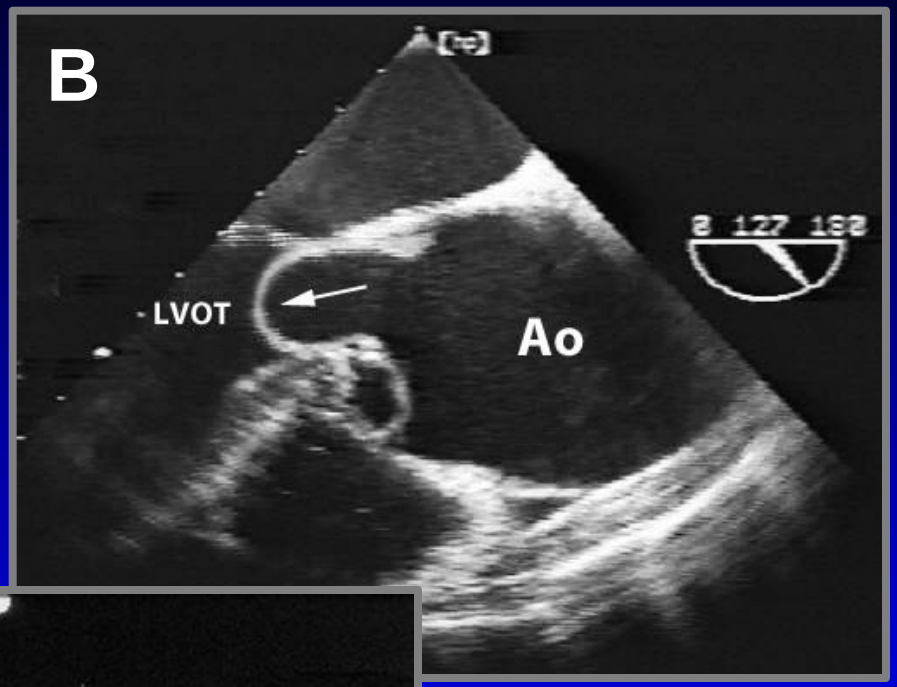

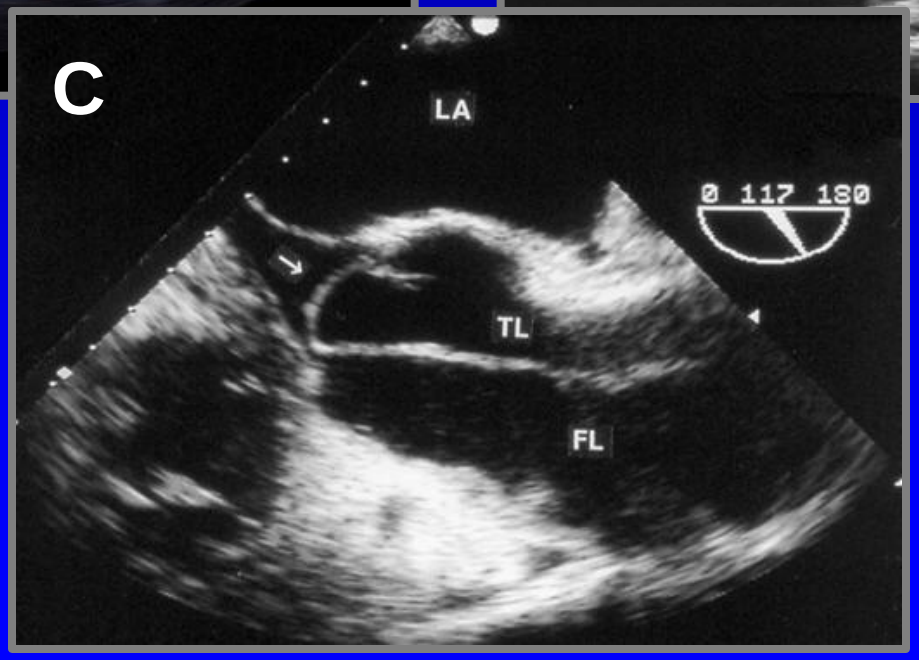

Cases

Case 1

Case 2

RM - 46 year old man

Known bicuspid aortic valve

S/P coarct repair (remote)

Sudden onset of severe chest pain

Syncope

Intramural Hematoma

“Atypical" Aortic Dissection (Intramural Hematoma)



Typical = Dissection flap and false lumen

"Atypical" = No dissection flap; Medial hematoma

"Atypical" Aortic Dissection (Intramural Hematoma)

- Prevalence 10-20% in CT/MRI/TEE studies
- Type III more common
- Normal size lumen
- False negative aortograms

Table 10 Prevalence of IMH (as percentage of aortic dissection or nontraumatic AAS)

Author	Year	n	%	Source
Mohr-Kahaly	1994	27/114	23%	420
Nienaber	1995	25/195	12.8%	421
Keren	1996	10/49	20%	422
Harris	1997	19/84	23%	423
Vilacosta	1997	15/88	17%	229
Nishigami	2000	59/130	45%	424
Ganaha	2002	66/725	9%	425
Evangelista	2003	68/302	22%	154
Attia (meta-analysis)	2009	—	17%	426
	Totals	**289/1,687**	**17%**	

Intramural Hematoma

Imaging Features

- Focal aortic wall thickening
- Preserved luminal shape with a smooth luminal border
- Absence of dissection flap and false lumen
- Echolucent regions may be present in the aortic wall

Note: Often missed by aortogram which is a luminogram

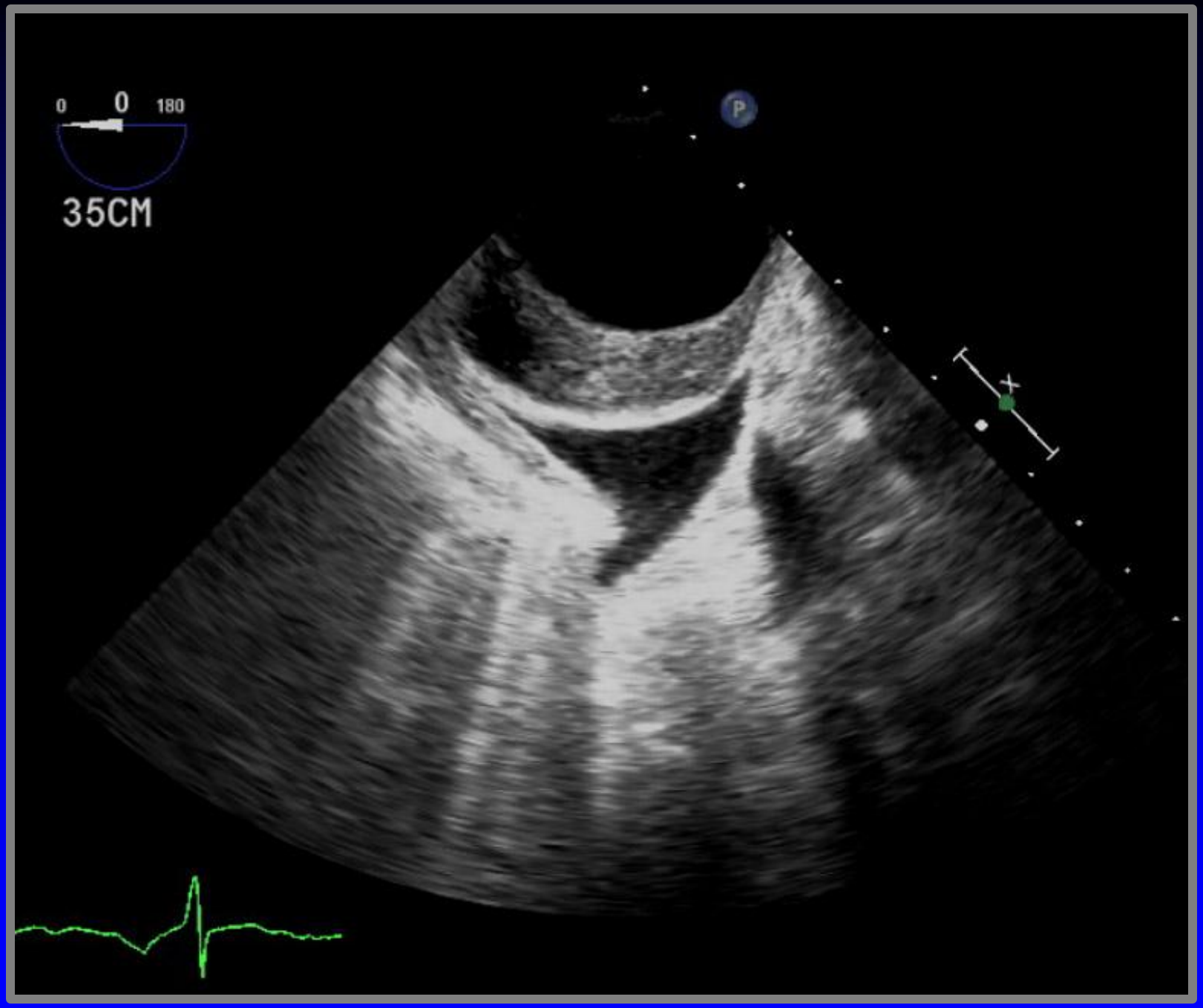
0
0
180
35CM
P

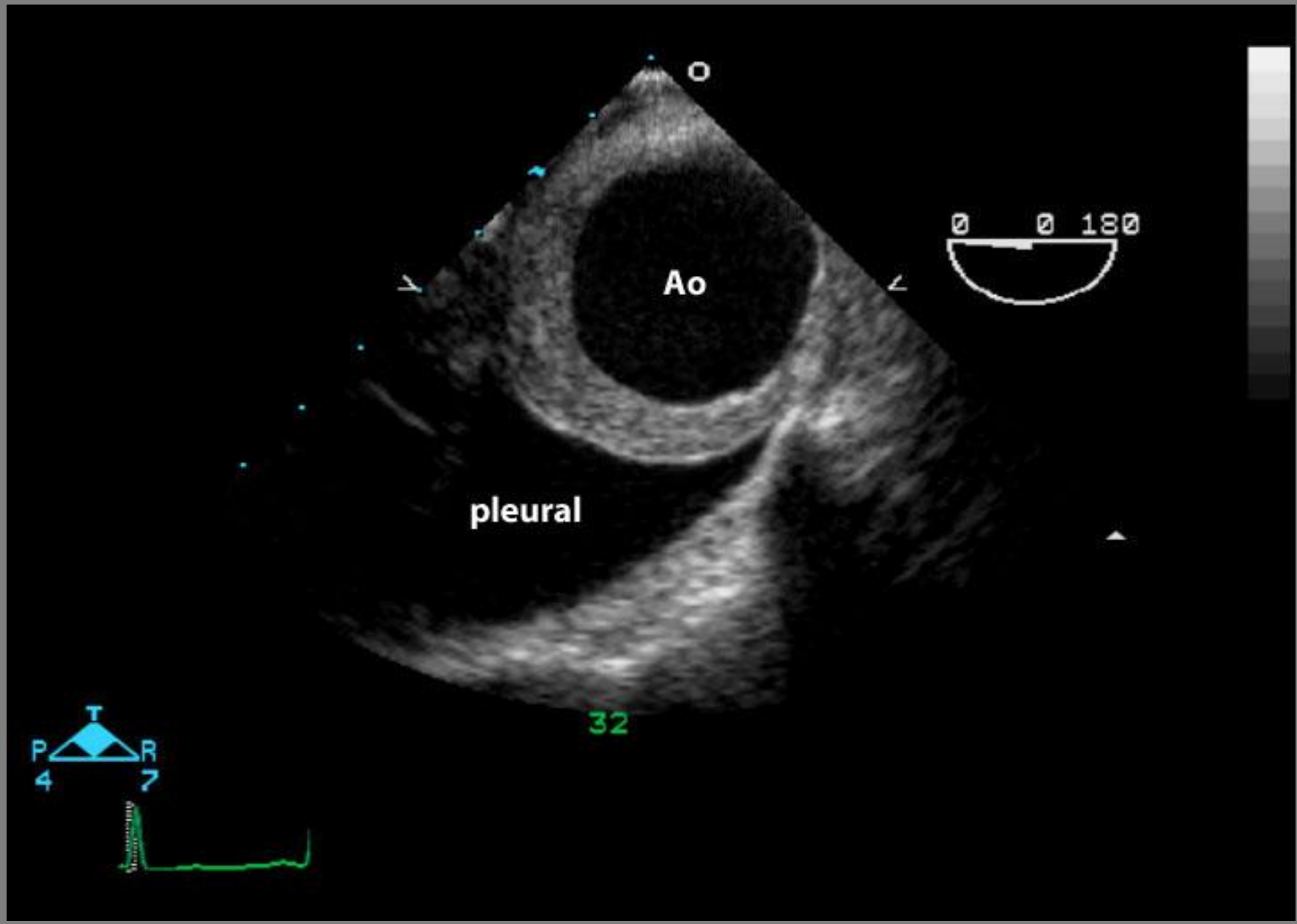
Ao
pleural
0 0 180
32
T
P R
4 7

Intramural Hematoma

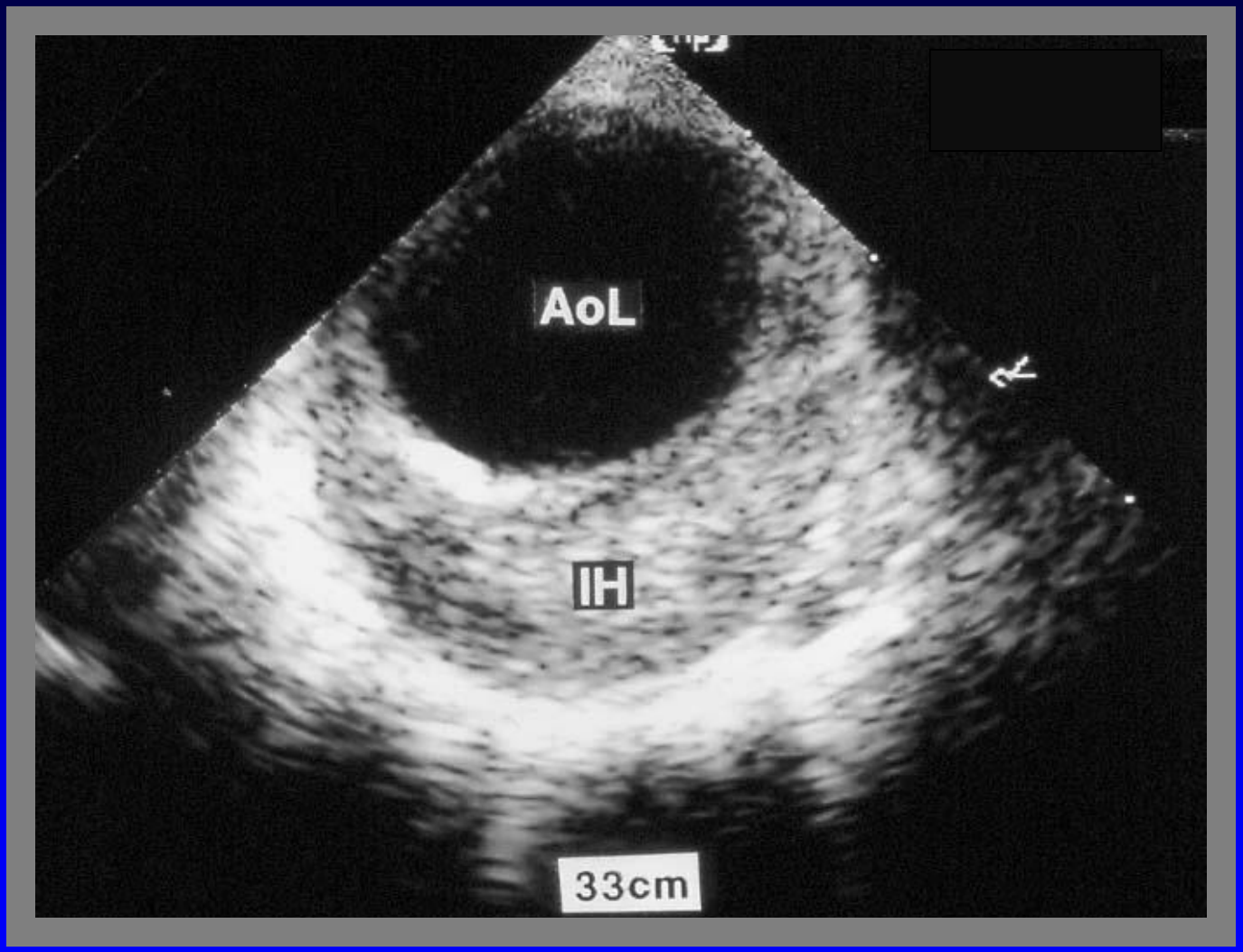

Intramural Hematoma
CT-scan

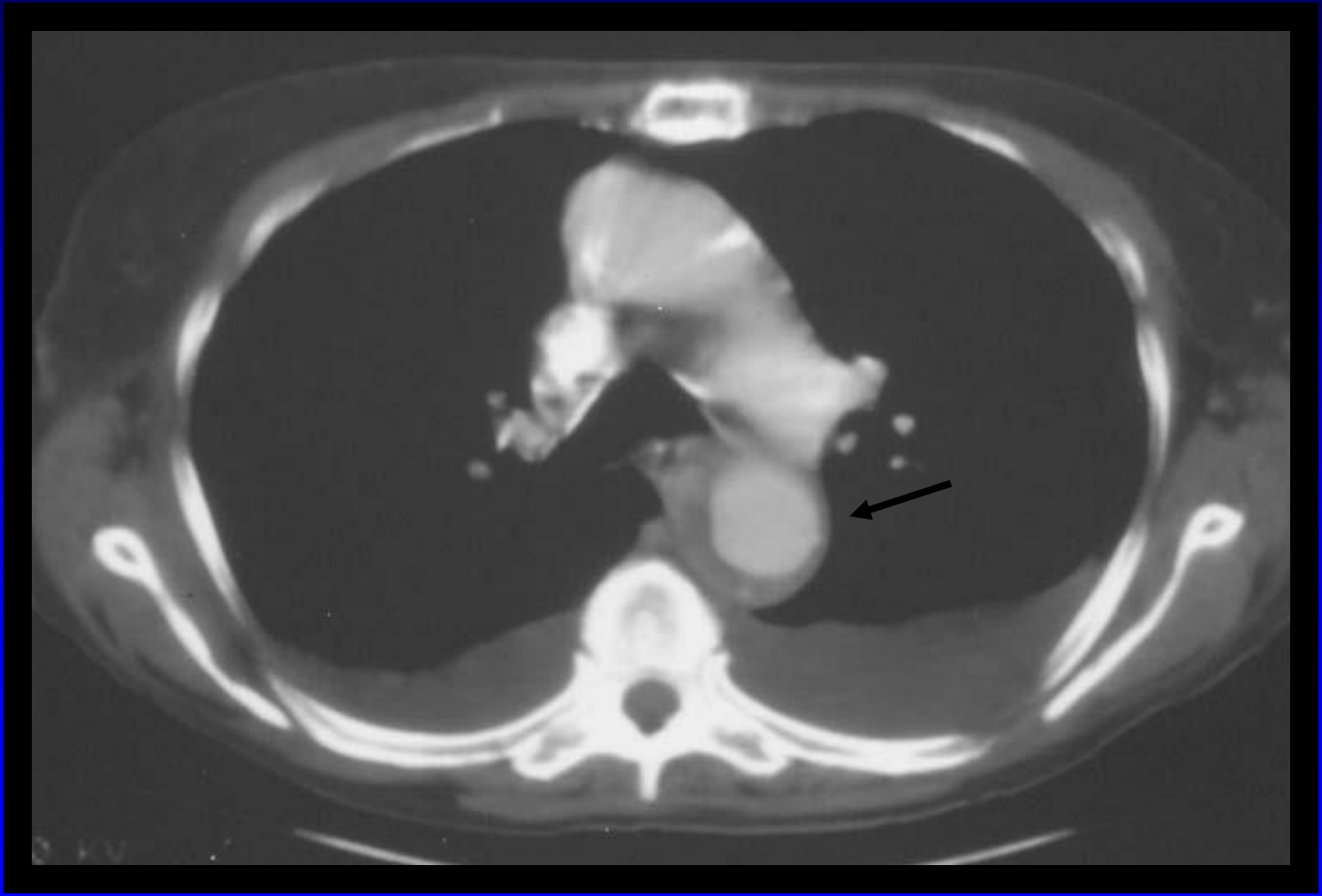

Intramural Hematoma

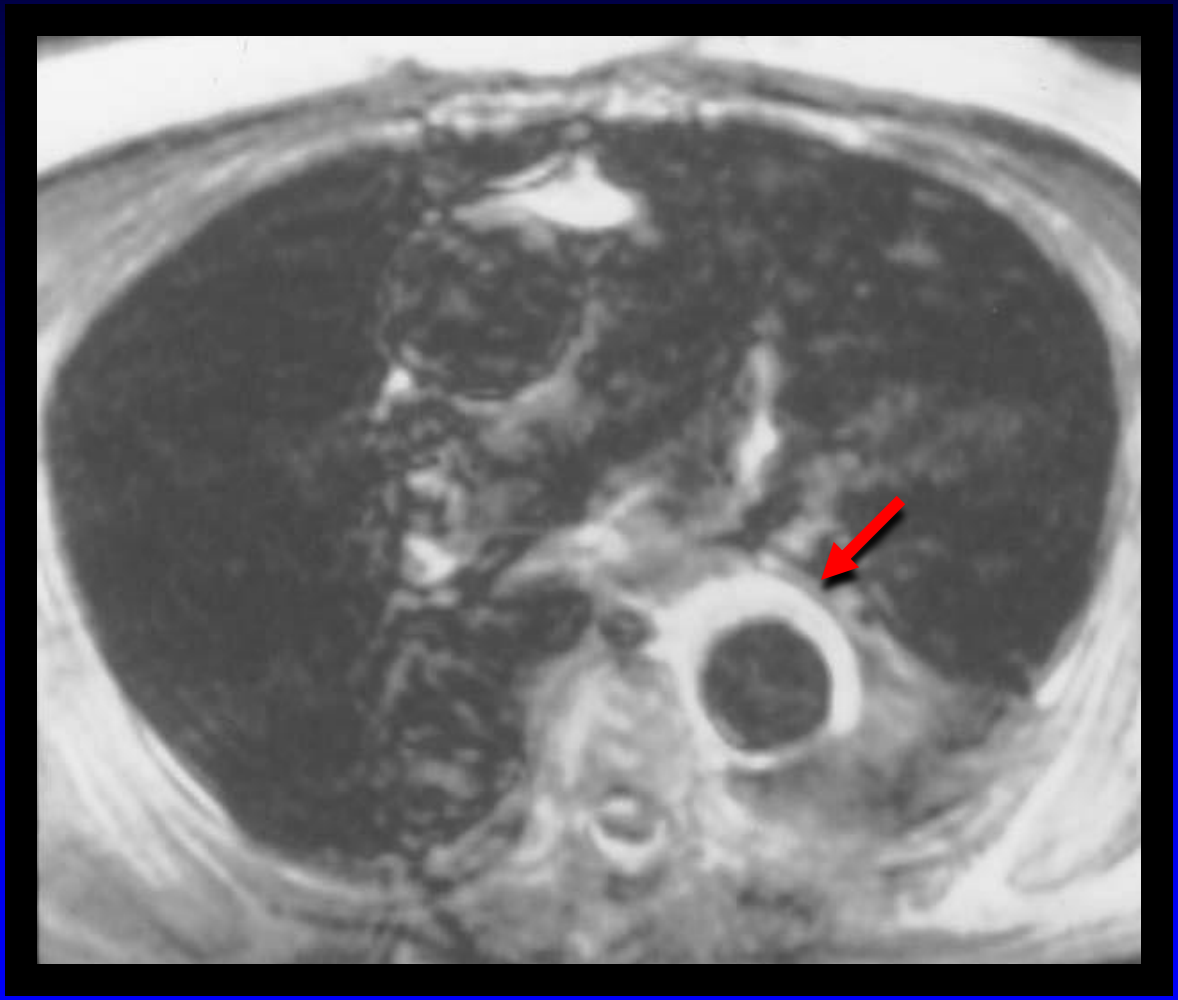

MRI

Case 3

Case 4

Summary

- Advances in imaging techniques have greatly increased our understanding of thoracic aortic diseases
- Indications for specific modality depends on:
  - Accuracy for specific diseases
  - Availability
  - Cost/benefit ratio
- TTE used most often for aortic root assessment

continued . . .

Summary

- CT-scan → high resolution of entire aorta including arch, mesenteric, and renal vessels
- MRI → greatest morphologic and dynamic information without radiation, but less widely available
- TEE → optimal procedure for guidance in OR safely performed on critically ill patients, even those on ventilators

Table 4 Comparison of five imaging modalities for diagnostic features of AAS

Diagnostic performance	CTA	TTE	TEE	MRA	Angiography
Sensitivity	+++	++	+++	+++	++
Specificity	+++	++	+++	+++	+++
Ability to detect IMH	+++	+	++	+++	–
Site of intimal tear	+++	–	++	+++	++
Presence of AR	–	+++	+++	++	+++
Coronary artery involvement	+	–	++	+	+++
Presence of pericardial effusion	++	+++	+++	++	–
Branch vessel involvement	++	–	+	++	+++

CTA, Computed tomographic angiography; +++, very positive; ++, positive; +, fair; –, no.
Adapted from Cigarroa *et al*.[182] and Isselbacher.[243]

Table 5 Practical assessment of five imaging modalities in the evaluation of suspected AAS

Advantages of modality	CTA	TTE	TEE	MRA	Angiography
Readily available	+++	+++	++	+	+
Quickly performed	+++	+++	++	+	+
Performed at bedside	–	+++	+++	–	–
Noninvasive	+++	+++	+	+++	–
No iodinated contrast	–	+++	+++	+++	–
No ionizing radiation	–	+++	+++	+++	–
Cost	++	+	++	++	+++

CTA, Computed tomographic angiography; +++, very positive; ++, positive; +, fair; –, no.
Adapted from Cigarroa *et al*.[182] and Isselbacher.[419]

The End